







Giant Inflammatory Polyposis of the Rectum as a Complication of Ulcerative Colitis

Theeran Gill¹ , Jaikumar Nallamuthu¹ , Shabbar Husain² , Wazir Azzam¹ , Firdaus Hayati³ ,
Ismail Sagap⁴ 

¹Department of General Surgery, 94 Armed Forces Hospital Terendak, Melaka, Malaysia

²Department of General Surgery, Hospital Angkatan Tentera Tuanku Mizan, Malaysia

³Department of Surgery, Faculty of Medicine and Health Sciences, Universiti Malaysia Sabah, Kota Kinabalu, Sabah, Malaysia

⁴Department of Surgery, Faculty of Medicine, Hospital Canselor Tuanku Muhriz, Cheras, Kuala Lumpur, Malaysia

Correspondence to: Firdaus Hayati; firdaushayati@gmail.com; m_firdaus@ums.edu.my

Received: 22 Jul 2021; Revised: 30 Jan 2021; Accepted: 07 Feb 2022; Available online: 28 Mar 2022

Summary

Inflammatory bowel disease is an emerging gastrointestinal disease in Malaysia. One of its rare complications includes giant inflammatory polyposis (GIP). A 39-year-old woman presented with worsening per rectal mucous discharge, associated with blood, colicky abdominal pain, and weight loss. A series of endoscopies at another hospital did not provide an inconclusive diagnosis. Another repeat colonoscopy showed a left-sided colitis with marked erythema and friability with islands of polyps; this was concluded to be an ulcerative colitis based on histopathology; thus, medical treatment was commenced. However, 2 months later, the patient presented with constipation, which required laxatives, as well as a worsened lower abdominal pain. Subsequent colonoscopy revealed obstruction-caused GIP at the mid rectum extending to

the lower rectum, which was confirmed by imaging modalities. She was diagnosed with obstructing GIP coupled with ulcerative colitis, and panproctocolectomy and ileal pouch anal anastomosis were planned.

Keywords: Case report, Colonoscopy, Inflammatory bowel disease, Ulcerative colitis

Ann Afr Surg. 2022; 19(3): 165-168

DOI: <http://dx.doi.org/10.4314/aas.v19i4.7>

Conflict of interest: None

Funding: None

© 2022 Author. This work is licensed under the Creative Commons Attribution 4.0 International License.

Introduction

Inflammatory bowel disease (IBD) was once considered rare in the Asian population. However, recent data have shown an emerging trend of IBD cases in Eastern Asia (1). In Malaysia, the mean crude incidence has doubled to 1.46 per 100,000 person-years (1). Giant inflammatory polyposis (GIP) is a rare complication of IBD. It is diagnosed when an inflammatory polyp is >1.5

cm in any given dimension or with the presence of filiform projections that look like “mass of worms” or a “fungating mass.” It occurs more frequently in ulcerative colitis than in Crohn disease (2, 3).

However, the presence of GIP in the rectum is very rare; if present, it appears continuous with the colon. Thus, dysplasia-associated lesions can be mistaken for

colorectal cancer, or even mass, because of its peculiar characteristics. Hence, histopathological examination is essential for differentiation, and a suitable mode of treatment should be applied. We present a case of GIP in the rectum without colonic involvement.

Case presentation

A 39-year-old woman, who was referred from another hospital, presented with a worsening per rectal mucous discharge associated with blood, colicky abdominal pain localized over the left iliac fossa and a weight loss of 9 kg. The patient has been experiencing mucous per rectal discharge with soiling for the past 10 years. Her past medical history revealed a bronchial asthma. Otherwise, there was no family history of cancer or drug abuse.

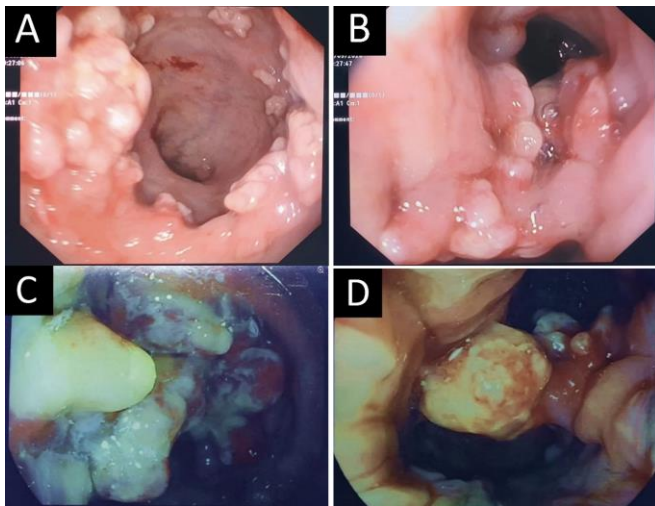


Figure 1. (A) Islands of friable pseudopolyps with minimal slough at the lower rectum. (B) Circumferential friable pseudopolyps of varying sizes, causing partial obstruction with cauliflower-like appearances. (C) Chronic active colitis with islands of pseudopolyps extending from the mid-rectum with slough. (D) Giant inflammatory polyposis (tubulovillous adenomas) >1.5 cm extending from the mid-rectum to the lower rectum with contact bleeding and slough.

Prior to the patient's visit at our hospital, she had undergone serial endoscopies at a district hospital. Her first colonoscopy showed low rectal polypoid growth with contact bleeding and slough 2 cm from the anal verge. The result of her histopathological examination was suggestive of a hyperplastic polypoid mucosa but was negative for malignancy. Her subsequent

endoscopy was scheduled a month later at the same hospital. Sigmoidoscopy was performed, and it revealed multiple growths up to 10 cm from the anal verge; although suspicious in nature, histopathological examination revealed inflamed granulation tissue instead.

The patient was then referred to our hospital for further investigation of her condition. On admission, she was hemodynamically stable. Physical examination showed mild tenderness to deep palpation from the suprapubic region extending to the left iliac fossa. The results of laboratory tests showed a hemoglobin count of 10 g/dL (normal range, 10–12 g/dL) and an albumin level of 34 g/L (normal range, 35–54 g/L), whereas other blood investigations were normal, including carcinoembryonic antigen. Her stool examination for *Clostridium difficile*, cytomegalovirus, ova, and cyst was normal. Subsequently, we proceeded with a colonoscopy.

Colonoscopy revealed a left-sided colitis with marked erythema, a friability with islands of polyps of various dimensions, contact bleeding, and slough located at the lower rectum (Figure 1A, 1B) (Partial Mayo Score Index 7). Biopsy showed chronic active colitis at the rectum, with features confirmatory of ulcerative colitis and tubulovillous adenoma with low-grade dysplasia. Based on the clinical presentation, laboratory test, and endoscopic and pathology findings, the patient was diagnosed with severe ulcerative colitis. She was started on suppository mesalazine 1 g twice a day and suppository Proctoserdy (cinchocaine hydrochloride and hydrocortisone) 2 tablets twice a day.

The patient was seen at our surgical outpatient clinic 2 months later with complaints of constipation that required laxatives and a worsening of lower abdominal pain. Repeated colonoscopy revealed multiple GIPs at the mid-rectum extending to the lower rectum (4 cm from the anal verge), which were causing obstruction (Figure 1C, 1D) with contact bleeding, mucus, and slough. The colon was normal. Post-colonoscopy, the patient underwent computed tomography of the thorax,

abdomen, and pelvis; magnetic resonance imaging of the pelvis; and barium enema.

The imaging results suggested features of ulcerative colitis with a narrowed sigmoid colon and an edematous rectal wall with multiple large polyp-like lesions measuring from 1.0 to 2.5 cm in length. Pararectal fat appeared clean, whereas other parts of the gastrointestinal tumor appeared normal. The barium enema had evidence of mucosal edema, and multiple filling defects were seen in the rectum (Figure 2). There were also scattered short areas of mucosal edema at the distal sigmoid colon. Otherwise, features were suggestive of an ulcerative colitis. The patient underwent panproctocolectomy and ileal pouch anal anastomosis after consultation, and postoperative recovery was uneventful. She was discharged after a week. The result of histopathological examination was consistent with ulcerative colitis with no evidence of malignancy. Follow-up in the surgical outpatient department clinic showed that she was well, with no complications or complaints.

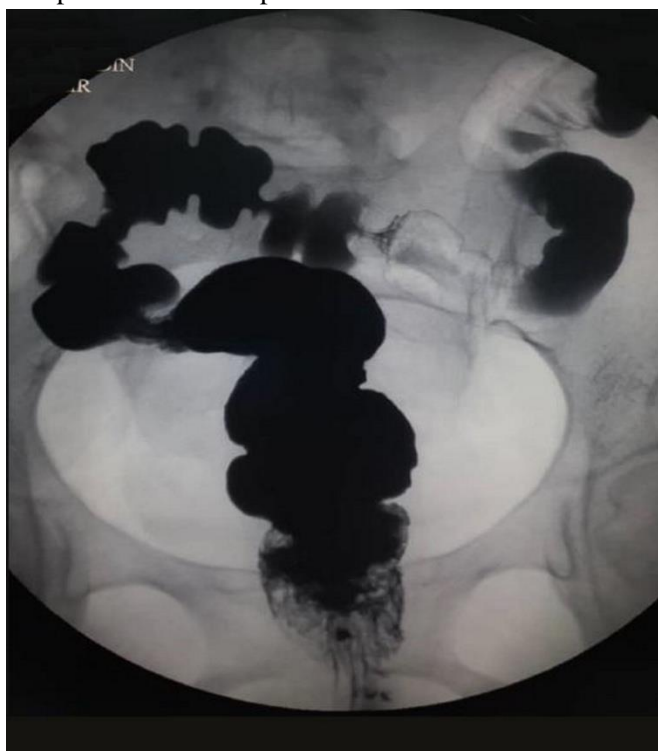

Figure 2. Barium enema showing narrowing of the rectum with normal colon.

All procedures were performed in accordance with the ethical standards laid down in the 1964 Declaration of Helsinki and its later amendments. Informed consent was obtained from the patient.

Discussion

The development of GIP may be related to the severity of the disease in ulcerative colitis, but it occurs in Crohn disease due to the duration of the disease itself (2). GIPs are an uncommon manifestation, and their presence can be correlated with the duration and the severity of IBD (4). They are most commonly found in the transverse colon, followed by the sigmoid and descending colon, cecum, and splenic and hepatic flexure, but rarely in the rectum (2, 5). The pathogenesis of GIP is multitude. Others proposed repeated peristalsis and the fecal stream as the cause of enlarged mucosal folds, whereas others proposed that GIP is formed when the ulcerated colonic mucosa is surrounded by granulation tissue leading to healing of the inflamed colonic mucosa in a polypoidal configuration during the regenerative phase (2, 4, 5). Yada et al. reported that the time from diagnosis of ulcerative colitis to GIP formation ranges from 3 to 276 months; it is suggested that GIP in ulcerative colitis patients may result in severe stenosis of the colon (6).

GIP can be asymptomatic, but it usually presents with diarrhea, rectal bleeding, abdominal pain, or even palpable abdominal mass (4). There have also been cases reported with partial or complete obstruction, protein-losing enteropathy, intussusception, and anemia (7, 8). Confusion may arise when diagnosing GIP radiologically and endoscopically. This is seen especially in patients with undiagnosed IBD or with dysplasia-associated lesions or mass in patients with IBD. Endoscopic biopsies with complete removal of the isolated GIP and histopathological examinations are of great importance and are essential for prompt diagnosis (4).

Medical treatments are opted first for those with symptoms of primary IBD or asymptomatic GIP. Nonetheless, surgical resections are the hallmark of treatment in cases with complications of GIP, such as

intussusception, failed endoscopic polypectomy, or colonic obstruction, as the recurrence of post-surgical resections has not been reported before (3). However, only one case of occult adenocarcinoma in GIP associated with ulcerative colitis has been reported in the literature, which was associated with multiple foci of dysplasia in other areas of pseudopolyp (9). The incidence of malignancy in a patient with ulcerative colitis is 3–5%, indicating that the risk of malignancy is equal in a patient having ulcerative colitis, with or without GIP (6).

Conclusion

The development of GIP is related to the severity of ulcerative colitis. It may present with intestinal obstruction and lower gastrointestinal bleed, besides being symptomatic. Although rare, it is most commonly found in the transverse colon, followed by the sigmoid and descending colon, cecum, and splenic and hepatic flexure, but rarely in the rectum. The presence of GIP in patients with ulcerative colitis does not increase the risk of malignancy compared with the presence in patients with ulcerative colitis only. The mainstay of treatment is still medical treatment with surgery reserved for complicated GIP.

Author contributions

All authors contributed equally in writing this manuscript.

Declaration of interests

The authors declare no conflict of interest.

References

1. Mokhtar NM, Nawawi KNM, Verasingam J, et al. A four-decade analysis of the incidence trends, sociodemographic and clinical characteristics of inflammatory bowel disease patients at single tertiary centre, Kuala Lumpur, Malaysia. *BMC Public Health*. 2019; 19: 550.
2. Abou Rached A, Saba J, El Masri L, et al. Obstructive giant inflammatory polyposis: is it related to the severity or the duration of the inflammatory bowel disease? Two case reports. *Case Rep Gastrointest Med*. 2018; 2018: 3251549.
3. Syal G, Budhraj V. Recurrent obstructive giant inflammatory polyposis of the colon. *ACG Case Rep J*. 2016; 3: e89.
4. Maggs JR, Browning LC, Warren BF, et al. Obstructing giant post-inflammatory polyposis in ulcerative colitis: case report and review of the literature. *J Crohns Colitis*. 2008; 2: 170-80.
5. Koga H, Iida M, Aoyagi K, et al. Generalized giant inflammatory polyposis in a patient with ulcerative colitis presenting with protein losing enteropathy. *Am J Gastroenterol*. 1995; 90: 829-31.
6. Yada S, Matsumoto T, Kudo T, et al. Colonic obstruction due to giant inflammatory polyposis in a patient with ulcerative colitis. *J Gastroenterol*. 2005; 40: 536-9.
7. Kusunoki M, Nishigami T, Yanagi H, et al. Occult cancer in localized giant pseudopolyposis. *Am J Gastroenterol*. 1992; 87: 379-81.
8. Okayama N, Itoh M, Yokoyama Y, et al. Total obliteration of colonic lumen by localized giant inflammatory polyposis in ulcerative colitis: report of a Japanese case. *Intern Med*. 1996; 35: 24-9.
9. Nagashima M, Sugishita Y, Moriyama A, et al. Tumor-like growth of giant inflammatory polyposis in a patient with ulcerative colitis. *Case Rep Gastroenterol*. 2013; 7: 352-7.